



PATIENT

Tristan Konefal

SPECIES

Feline

BREED

DMH

SEX

Male Neutered

AGE

5 years

WEIGHT

13.15lbs

INTERPRETED BY

Maggie Machen
Lamy, DVM
DACVIM (Cardiology)

PRESENTING CLINICAL SIGNS

History: Recheck echo. History of borderline IVS thickness and slightly enlarged papillary muscles, rest WNL on prior echocardiogram (6/2/21 MML). Currently, doing well at home. Good appetite and can be playful. Exam: Exam: NSR, grade III/VI murmur noted on sternum, PSS, lung fields clear, compressible thorax. BP: 130mmHg x 5. No medications.
-Pertinent previous echo findings (6/2/21 MML): LA 1.3 cm; LA:Ao 1.3; IVS 0.56 cm; PW 0.46 cm.

ECHOCARDIOGRAM FINDINGS

2D, m-mode, color flow and Doppler imaging is available.
Left ventricle: The LV diameter is normal with adequate myocardial function. The septum measures borderline in dimension; however, the remainder of the LV walls are normal. There is a mildly hyperechoic endocardium consistent with fibrosis. The papillary muscles are mildly remodeled and mildly hypertrophied. The endocardium appears mildly remodeled.
Left atrium: The left atrium is borderline in dimension. No obvious spontaneous contrast or thrombi seen.
Mitral valve: The mitral valve is normal in structure. Slight systolic anterior motion is suspected on 2D imaging. No mitral regurgitation.
Aortic valve/Aorta: The aortic valve is normal in morphology and mobility. Normal aortic outflow velocity. No aortic insufficiency.
Right ventricle: Normal right ventricular diameter and morphology indicating no overt evidence of pulmonary arterial hypertension.
Right atrium: The right atrium is normal in dimension.
Tricuspid valve: The tricuspid valve appears normal with no tricuspid regurgitation.
Pulmonic valve/Pulmonary artery: The pulmonic valve is normal in morphology and mobility. No pulmonic insufficiency. Normal RVOT velocity.
Pericardium/other: No pericardial or pleural effusion noted. No obvious cardiac masses.
Heart rhythm: ECG reveals a sinus rhythm with an average HR of 190bpm.

IMAGING PERFORMED BY

Pamela Harrigan,
RDCS

HOSPITAL NAME

Mass Veterinary Services

REFERRING VET

Dr. Masloski

INVOICE

22346

DATE

12/8/21

2-Dimensional Measurements

Ao diam (cm)	1.0
LA diam (cm)	1.3
LA:Ao (Swe)	1.3
IVS thickness (cm)	0.55
LVID diastole (cm)	1.4
PW thickness (cm)	0.48
LVID systole (cm)	0.5
FS (%)	66

Doppler Measurements

PV Vmax (m/s)	1.2
AoV Vmax (m/s)	1.6
MR Vmax (m/s)	NA
TR Vmax (m/s)	NA
TR PG (mmHg)	NA

INTERPRETATION OF THE FINDINGS

Unchanged cardiac structural appearance. The septum remains borderline in dimension with no obvious evidence of progression. The murmur appears largely benign in origin and there is no evidence of progressive LA pressure elevation. No additional issues are identified.

Given these findings, no medications are indicated. Prognosis is guarded going forward given the young age of the patient and lifelong risk for progression.



PATIENT

Tristan Konefal

SPECIES

Feline

BREED

DMH

SEX

Male Neutered

AGE

5 years

WEIGHT

13.15lbs

INTERPRETED BY

Maggie Machen Lamy, DVM
DACVIM (Cardiology)

IMAGING PERFORMED BY

Pamela Harrigan, RDCS

HOSPITAL NAME

Mass Veterinary Services

REFERRING VET

Dr. Masloski

INVOICE

22346

DATE

12/8/21

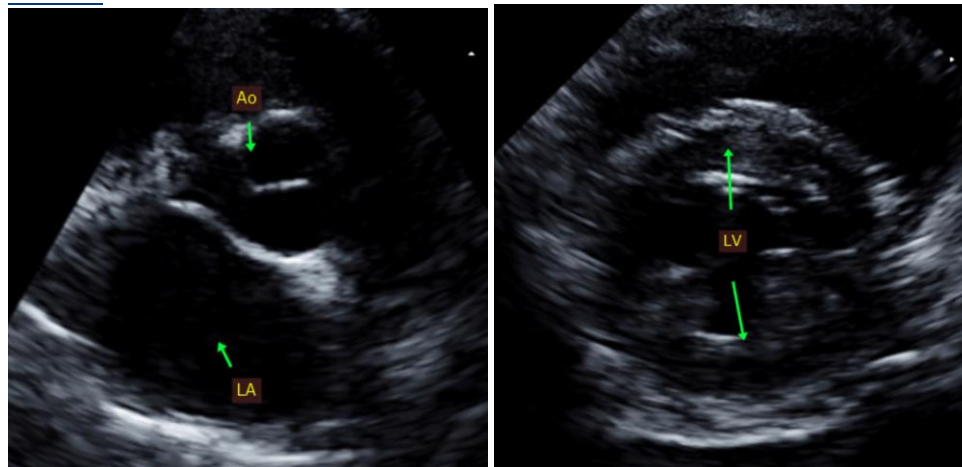
RECOMMENDATIONS

- Given these findings, no medications are indicated.
- Monitor BP and T4 every 6 months.
- Monitor for any clinical evidence of cardiac compromise, including respiratory changes and/or signs of a blood clot event (paralysis, neurologic changes, etc.).
- Anesthetic risk is considered mild, however judicious IV fluid rates are advised to avoid fluid overload. Additionally, drugs that stimulate heart rate should be avoided unless clinically necessary (glycopyrrolate, atropine). Avoid vasodilators as this may worsen the obstruction. A reasonable protocol includes opioid/benzodiazepine premedication, propofol induction, isoflurane maintenance. Additionally, steroids should be used with caution on older cats, as even a 'normal' geriatric heart can develop evidence of intolerance and fluid retention.

PLAN

- Recommend recheck echocardiogram in 6-12 months to reassess murmur origin and screen for progressive LVH.

IMAGES



The information and recommendations provided are based on the images presented by the referring veterinarian. No evaluation can be communicated regarding pathology that was not visible in the image/video clips provided.

Thank you for this referral. This report was generated using transcription software, and minor dictation errors may be present. If the clinical or image interpretation does not parallel your findings or if I can be of any further assistance, please contact me.

Maggie Machen Lamy, DVM
Diplomate of the American College of Veterinary Internal Medicine (Cardiology)
info@sonopath.com

Echocardiogram performed by: Pamela Harrigan, RDCS
Pet Animal Ultrasound Service (4paus.com)